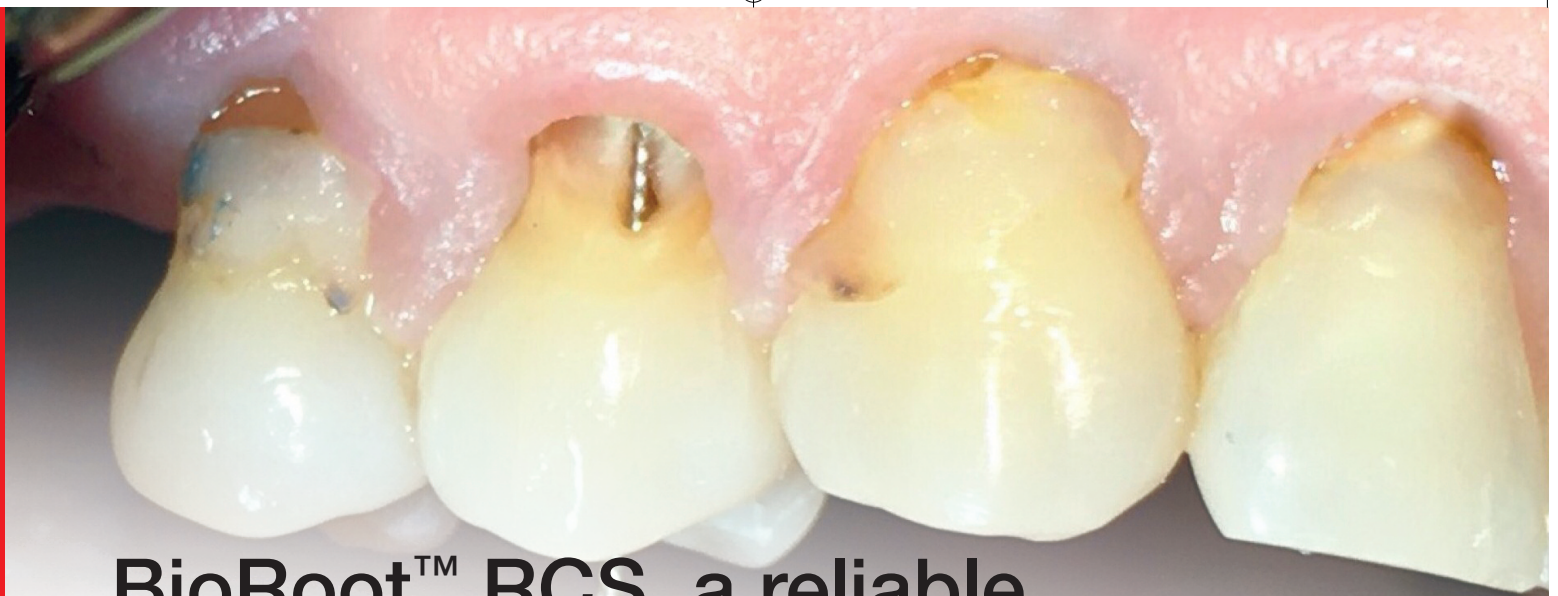



BioRoot™ RCS, a reliable bioceramic material for root canal obturation

Jenner O. Argueta D.D.S. – M.Sc.

Introduction

During the treatment of root canals it is practically impossible to obtain an environment completely free of bacteria (Markus Haapasalo, Shen, Qian, & Gao, 2010); considering this fact, the root obturation procedure must contain the remaining microorganisms, keeping them deprived of nutrients and of an environment capable of reactivating their metabolism and growth (Simon, 2016; Siqueira, Araujo, & García, 1997).

The majority of modern obturation techniques involve the use of gutta-percha combined with sealing cement; the latter is used with a view to filling in the interface between the root dentin and the gutta-percha. Cement fluidity is an important factor in ensuring that it will reach the areas of the canal that cannot be accessed with root-shaping instruments, but are receptive to chemical disinfection processes applied by means of the various irrigation techniques (Siqueira, Rocas, Favieri, & Lima, 2000). It is advisable to use a minimal amount of sealing cement in proportion to the amount of gutta-percha used, when resin-, zinc oxide-eugenol-, or calcium hydroxide-based cements are to be used, since the use of substantial amounts of cement generates the possibility of degradation

and leakage, which may lead to bacterial recontamination, and thus causing over time the failure of the endodontic treatment (Simon, 2016).

Of the obturation techniques discussed in the literature, single-cone obturation is one of the most sensitive to post-operative leakage since the gutta-percha cones used with the instrumentation system are not perfectly compatible with the final shape of the root canal (Schäfer, Köster, & Bürklein, 2013).

Due to the variability of gutta-percha cones and the irregularities specific to root canal systems, the sealing cement used must be physically stable, must provide good apical sealing, and must have the ability to set in the presence of the moisture present in dentin and periradicular tissues. Single-cone obturation is one of the simplest and quickest methods to use, but is very questionable if applied with non-bioceramic cements, since the presence of large amounts of sealant in the obturation may cause leakage problems over time (Simon, 2016).

Bioceramic cements are an interesting option for the use of the single-cone technique; their physical characteristics render them capable of providing a stable three-dimensional seal in the

necessary time frame (Daculsi, Laboux, Malard, & Weiss, 2003), all without the need for compaction procedures, whether warm or cold. These materials are able to set in humid environments; this point has major relevance considering the fact that dentin has a moisture content of approximately 20%, and that work in moisture-saturated environments is a constant in the dental profession (K. Koch, Brave, & Nasseh, 2010).

Bioceramic cements are divided into three basic groups.

- 1: Bioinert high strength cements;
- 2: Bioactive cements that form chemical bonds with mineralized tissue; and
- 3: Biodegradable materials that integrate actively with the body's metabolic processes (K. Koch & Brave, 2009).

Due to their high stability and sealing properties, bioceramic cements can be used in combination with gutta-percha as part of a single-cone technique, or directly inside the root canal to seal their entire length. Though bioceramic cement may function as an obturation material, it is advisable that a gutta-percha cone be used to

convey it to the inside of the canal and hold it in position at working length or one millimeter short, to leave a route for re-treatment, if necessary in the future. This last procedure would be a real challenge for the operator if no access route were available for re-treatment. The single-cone obturation technique can be used safely in combination with bioceramic cements, due to their previously mentioned physical and dimensional stability, good sealing properties, antibacterial potential, biocompatibility, and bioactivity capable of stimulating periapical tissue repair (Trope & Debelian, 2014).

BioRoot™ RCS is a relatively new bioceramic cement based on tri-calcium silicate, zirconium oxide as a biocompatible radio-opacifying material and a hydrophilic polymer to improve its adhesion properties; the liquid mostly contains water with calcium chloride as a setting modifier (Nakov et al., 2015). The working time is approximately 15 minutes and the total setting time is 4 hours within the root canal (Simon, 2016). Next, we present a clinical case performed using BioRoot™ RCS as a root filling cement.

Clinical Case

A 45-year-old patient reported the loss of a cervical restoration in tooth 12, the caries present in the area was removed to verify the extent of the lesion (*Fig. 1*). Thermal sensitivity tests and periapical radiographs were performed (*Fig. 2*). In consideration of all the signs and symptoms

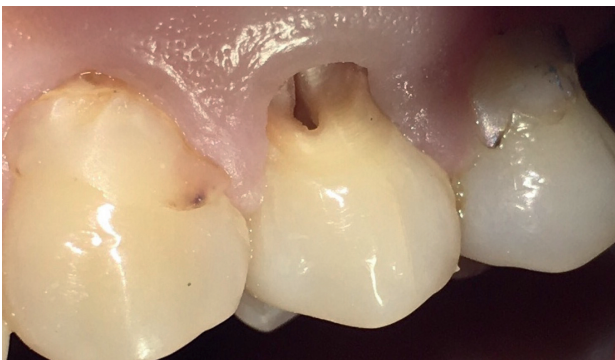

Fig. 1: Cervical cavity after elimination of carious lesion; the root canal was exposed during mechanical tissue removal.

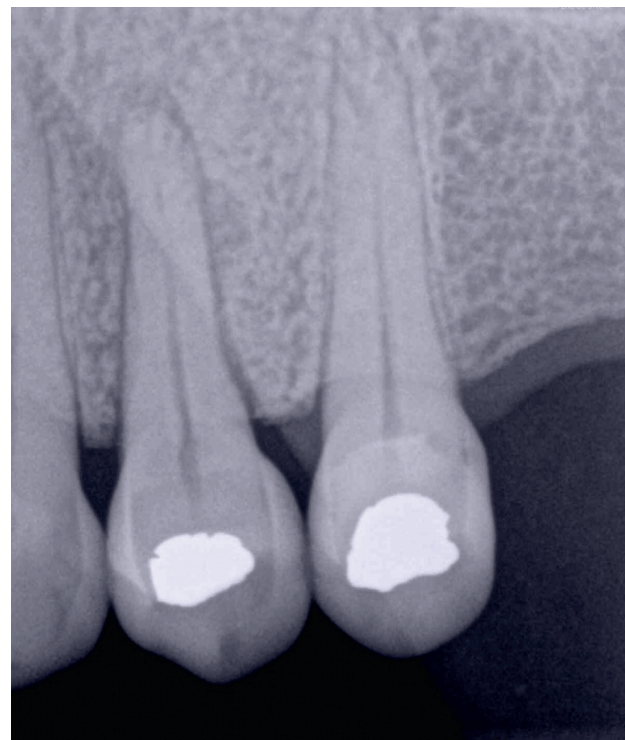


Fig. 2: Initial x-ray - note the periapical areas shown.

present, a diagnosis of pulpal necrosis with asymptomatic apical periodontitis was made. The root canal treatment was performed in one session, first restoring the cervical cavity with resin-reinforced glass ionomer (*Fig. 3*). To prevent the restoration material from causing an obstruction within the duct, a No. 20 k-file was placed in the cervical radicular area (*Fig. 4*). With the operating environment properly prepared to achieve good isolation, the canals were permeabilized to a #15.02 hand file with the pulp chamber filled with EDTA 17% Gel (MD-Chel-cream) after said chamber was first disinfected with sodium hypochlorite 5.25%. The canal system configuration was determined to be Vertucci Type IV (Altunsoy, Nur, Aglarci, Colak, & Gungor, 2014).

Mechanized instrumentation was performed with TF Adaptive files using adaptive motion, after determining the working length using the Rotor electronic apex locator. During the procedure, a #25.06 instrument was separated in the apical region of the palatal canal (*Fig. 5*); the latter was bypassed and then obturated using the hydraulic condensation technique (J. Koch & Brave, 2012) using BioRoot™ RCS as a sealing cement.

The last x-ray shows cement puffs in both roots (*Fig. 6 and 7*). The patient was asymptomatic during the postoperative period. At the re-evaluation appointments, healing was observed to be ongoing at 5 months (*fig. 8*) and complete healing was observed at the final re-evaluation, performed 9 months after the initial procedure was completed (*fig. 9*).

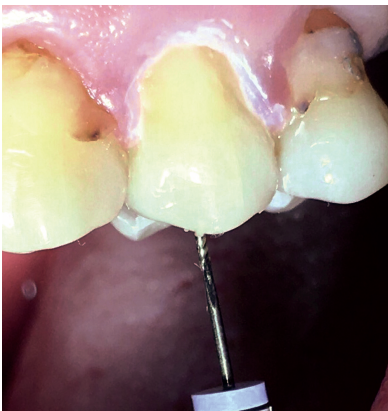

Fig. 3: Photograph of the restoration in the cervical area prior to the root canal treatment.

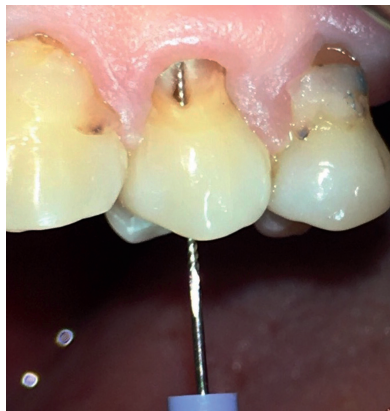

Fig. 4: Placement of a K-file in the buccal canal prior to obturation placement in the cervical region; the instrument was put in place to keep the pathway permeable.

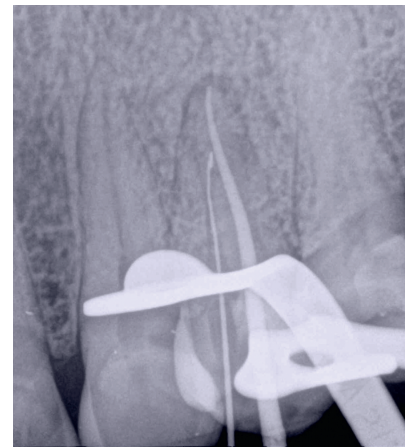


Fig. 5: Separated instrument in the palatal canal; this was bypassed prior to the final obturation.

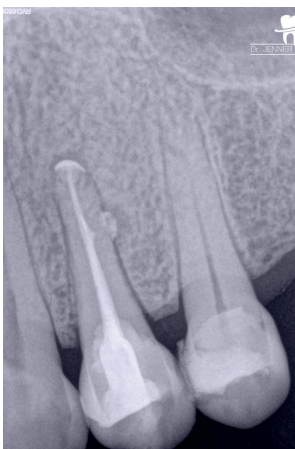


Fig. 6: Final x-ray taken at an orthoradial angle; cement puffs can be observed in the periapical regions.

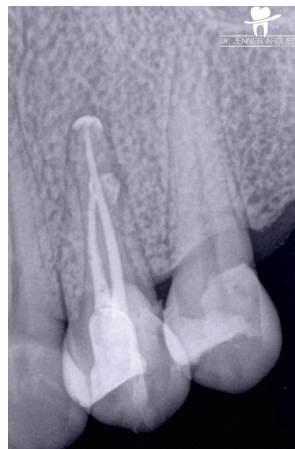


Fig. 7: Final mesial x-ray; the separated instrument included in the final obturation can be observed.

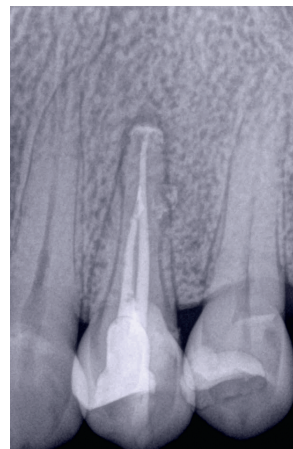


Fig. 8: Re-evaluation at 5 months, the periapical areas are seen to be in the process of healing; part of the cement has been resorbed by the organism.

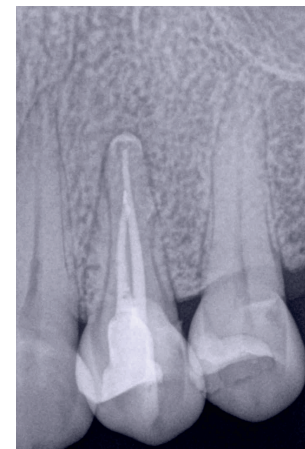


Fig. 9: Re-evaluation at 9 months, apical lesions have completely healed. There has been partial resorption of the apically extruded cement.

Discussion

Root canal treatment is performed in view of avoiding periradicular lesions or otherwise of promoting an adequate environment for the body to be able to heal the existing lesion or pathology (Peters, 2004); the use of cements to seal the interface between tooth and gutta-percha is of crucial importance in achieving the objective mentioned earlier. Bioceramic cements such as BioRoot™ RCS are made from a combination of silicate and calcium phosphate; the bonding of these components provides physical and biological properties such as: Alkaline PH, anti-bacterial activity and bio-compatibility (Candeiro, Correia, Duarte, Ribeiro-Siqueira, & Gavini, 2012). Another advantage of this type of material is its ability to form hydroxyapatite and even bring about bonding between dentin and root canal obturation material during the setting process (Loushine, Bryan, & W., 2011). The latter characteristic is of high importance in repair processes, since, as can be observed in the present case, the release of ions linked to mineralization processes may promote the complete and relatively rapid healing of the periapical lesions. The biocompatibility of the cement is also apparent in this case: despite

the puffs that were produced because of the obturation technique used, the patient remained completely asymptomatic and symptom-free. One of the most common techniques of root obturation using bioceramic cements is to place small amounts of cement into the canal, bringing it up to the proper length using paper tips; the use of paper tips also has the advantage of eliminating the excess moisture present in the cement and limiting the apical pressure exerted. After the cement has been placed as desired, a gutta-percha cone is inserted to constitute the central part of the obturation (M. Haapasalo, Parhar, Huang, Way, & James, 2015).

BioRoot™ RCS has been increasingly popular since its introduction, and has become one of the materials of choice in cases of open apices and extensive periapical lesions; its popularity is due in large measure to its excellent biocompatibility, remarkable sealing properties, hydrophilicity, and its capacity to promote both healing and tissue mineralization (Simon, 2016) (J. D. Koch & Brave, 2012). Together these properties make BioRoot™ RCS a very interesting option when choosing an obturation technique.



Author:

Jenner O. Argueta Zepeda

Dental surgeon

Master in Endodontics

President, Guatemalan Endodontics Academy.

Professor of Endodontics at Mariano Gálvez University, Guatemala.

International Lecturer.

Researcher at the Guatemalan National Council for Science and Technology (CONCYT).

Member of the American Association of Endodontists.

References

- Altunsoy, M., Nur, B. G., Aglarci, O. S., Colak, M., & Gungor, E. (2014). A cone-beam computed tomography study of root canal morphology of maxillary and mandibular premolars in a Turkish population. *Acta Odontol Scand*, 72(8), 701-706. doi:10.3109/00016357.2014.898091
- Candeiro, G. T., Correia, F. C., Duarte, M. A., Ribeiro-Siqueira, D. C., & Gavini, G. (2012). Evaluation of radiopacity, pH, release of calcium ions, and flow of a bioceramic root canal sealer. *J Endod*, 38(6), 842-845. doi:10.1016/j.joen.2012.02.029
- Daculsi, G., Laboux, O., Malard, O., & Weiss, P. (2003). current state of the art of biphasic calcium phosphate bioceramics. *Journal of Materials Science: Materials in Medicine*, 195-200.
- Haapasalo, M., Parhar, M., Huang, X., Way, X., & James, L. (2015). Clinical use of bioceramic materials. *Endodontic Topics*, 32, 97-117.
- Haapasalo, M., Shen, Y., Qian, W., & Gao, Y. (2010). Irrigation in Endodontics. *Dental Clinics*, 54.
- Koch, J. D., & Brave, D. (2012). Bioceramics, Part 1: The Clinician's Viewpoint. *Dent Today*.
- Koch, K., & Brave, D. (2009). Endosequence: melding endodontics with restorative dentistry, part 3. *Dent Today*, 28(3).
- Koch, K., Brave, G., & Nasseh, A. A. (2010). Bioceramic technology, Closing the endo-restorative circle, part 2. *Dent Today*, 29(3).
- Loushine, B. A., Bryan, T. E., & W., L. S. (2011). Setting properties and cytotoxicity evaluation of a premixed bioceramic root canal sealer. *Journal of Endodontics*, 37(7).
- Nakov, D., Uzunoglu, E., Ardila-Osorio, H., Baudry, A., Richard, G., & Kellermann, O. (2015). Bioactivity of BioRoot™ RCS, a root canal sealer, via A4 mouse pulpal stem cells in vitro. *Dental Materials*, 31(11).
- Peters, O. A. (2004). Current challenges and concepts in the preparation of root canal systems: a review. *J Endod*, 30(8), 559-567.
- Schäfer, E., Köster, M., & Bürklein, S. (2013). Percentage of gutta-percha-filled areas in canals instrumented with nickeltitanium systems and obturated with matching single cones. *Journal of Endodontics*, 39(7).
- Simon, S. F., T. (2016). BioRoot RCS a new biomaterial for root canal filling. *Septodont Case Studies Collection*, 13, 4-10.
- Siqueira, J. F., Jr., Araujo, M. C. P., & García, P. F. (1997). Histological evaluation of the effectiveness of five instrumentation techniques for cleaning the apical third of root canals. *Journal of Endodontics*, 23(8).
- Siqueira, J. F., Jr., Rocas, I. N., Favieri, A., & Lima, K. C. (2000). Chemomechanical reduction of the bacterial population in the root canal after instrumentation and irrigation with 1%, 2.5%, and 5.25% sodium hypochlorite. *J Endod*, 26(6), 331-334. doi:10.1097/00004770-200006000-00006
- Trope, M., & Debelian, G. (2014). Bioceramic Technology in Endodontics. *Inside Dentistry*.